

The American Journal of Sports Medicine

<http://ajs.sagepub.com/>

Ultrasound-Guided Injection of Platelet-Rich Plasma and Hyaluronic Acid, Separately and in Combination, for Hip Osteoarthritis: A Randomized Controlled Study

Dante Dallari, Cesare Stagni, Nicola Rani, Giacomo Sabbioni, Patrizia Pelotti, Paola Torricelli, Matilde Tschon and
Gianluca Giavaresi

Am J Sports Med published online January 21, 2016

DOI: 10.1177/0363546515620383

The online version of this article can be found at:

<http://ajs.sagepub.com/content/early/2016/01/21/0363546515620383>

Published by:



<http://www.sagepublications.com>

On behalf of:

American Orthopaedic Society for Sports Medicine



Additional services and information for *The American Journal of Sports Medicine* can be found at:

Published online January 21, 2016 in advance of the print journal.

P<P

Email Alerts: <http://ajs.sagepub.com/cgi/alerts>

Subscriptions: <http://ajs.sagepub.com/subscriptions>

Reprints: <http://www.sagepub.com/journalsReprints.nav>

Permissions: <http://www.sagepub.com/journalsPermissions.nav>

>> [OnlineFirst Version of Record](#) - Jan 21, 2016

[What is This?](#)

Ultrasound-Guided Injection of Platelet-Rich Plasma and Hyaluronic Acid, Separately and in Combination, for Hip Osteoarthritis

A Randomized Controlled Study

Dante Dallari,^{*†} MD, Cesare Stagni,[†] MD, Nicola Rani,[†] MD, Giacomo Sabbioni,[†] MD, Patrizia Pelotti,[‡] MD, Paola Torricelli,[§] BSc, Matilde Tschon,[§] PhD, and Gianluca Giavaresi,[§] MD
Investigation performed at Rizzoli Orthopedic Institute, Bologna, Italy

Background: The effectiveness of intra-articular platelet-rich plasma (PRP) injections has been evaluated in knee chondroplasty and osteoarthritis (OA); however, little evidence of its efficacy in hip OA exists.

Purpose: To compare the therapeutic efficacy of autologous PRP, hyaluronic acid (HA), or a combination of both (PRP+HA) in hip OA.

Study Design: Randomized controlled trial; Level of evidence, 1.

Methods: Patients aged between 18 and 65 years who were treated with outpatient surgery and who had hip OA and pain intensity at baseline of >20 on a 100-mm visual analog scale (VAS) were recruited for this study. Exclusion criteria were extensive surgery; presence of excessive deformities; or rheumatic, infective, cardiovascular, or immune system disorders. The primary outcome measure was a change in pain intensity as assessed by the VAS at 2, 6, and 12 months after treatment. Secondary outcome measures were the Harris Hip Score, Western Ontario and McMaster Universities Osteoarthritis Index (WOMAC), and concentration of growth factors in PRP and their correlation with clinical outcomes. Clinical outcomes were evaluated by assessors and collectors blinded to the type of treatment administered.

Results: A total of 111 patients were randomly assigned to 3 groups and received 3 weekly injections of either PRP (44 patients), PRP+HA (31 patients), or HA (36 patients). At all follow-ups, the PRP group had the lowest VAS scores. In particular, at 6-month follow-up, the mean VAS score was 21 (95% CI, 15-28) in the PRP group, 35 (95% CI, 26-45) in the PRP+HA group, and 44 (95% CI, 36-52) in the HA group ($P < .0005$ [PRP vs HA] and $P = .007$ [PRP vs PRP+HA]; $F = 0.663$). The WOMAC score of the PRP group was significantly better at 2-month follow-up (mean, 73; 95% CI, 68-78) and 6-month follow-up (mean, 72; 95% CI, 67-76) but not at 12-month follow-up. A significant, "moderate" correlation was found between interleukin-10 and variations of the VAS score ($r = 0.392$; $P = .040$). Significant improvements were achieved in reducing pain and ameliorating quality of life and functional recovery.

Conclusion: Results indicated that intra-articular PRP injections offer a significant clinical improvement in patients with hip OA without relevant side effects. The benefit was significantly more stable up to 12 months as compared with the other tested treatments. The addition of PRP+HA did not lead to a significant improvement in pain symptoms.

Keywords: platelet-rich plasma; hyaluronic acid; osteoarthritis; hip; intra-articular injection

*Address correspondence to Dante Dallari, Conservative Orthopedic Surgery and Innovative Techniques Ward, Rizzoli Orthopedic Institute, Via G.C. Pupilli 1, 40136 Bologna, Italy (email: dante.dallari@ior.it).

[†]Conservative Orthopedic Surgery and Innovative Techniques Ward, Rizzoli Orthopedic Institute, Bologna, Italy.

[‡]Radiology and Diagnostic Imaging Department, Rizzoli Orthopedic Institute, Bologna, Italy.

[§]Preclinical and Surgical Studies Laboratory, Rizzoli Orthopedic Institute, Bologna, Italy.

The authors declared that they have no conflicts of interest in the authorship and publication of this contribution.

Osteoarthritis (OA) is a slowly evolving process, characterized by joint pain, stiffness, and loss of range of motion. Overall, as many as 40% of those aged over 65 years in the community may have symptomatic OA of the knee or hip.^{1,9} The hip is a frequent site for OA, and the prevalence ranges from 7% to 25% in white patients aged over 55 years.² OA results from a complex interaction of biomechanical and biochemical factors and is characterized by cartilage disruption and hypertrophy of bone. Intra-articular proinflammatory cytokines and proteinases in OA interfere with the synthesis of hyaluronic acid (HA), a complex glycosaminoglycan composed of repeated disaccharide units to form a linear polymer, resulting in HA with a significantly reduced molecular weight and a reduction in synovial fluid

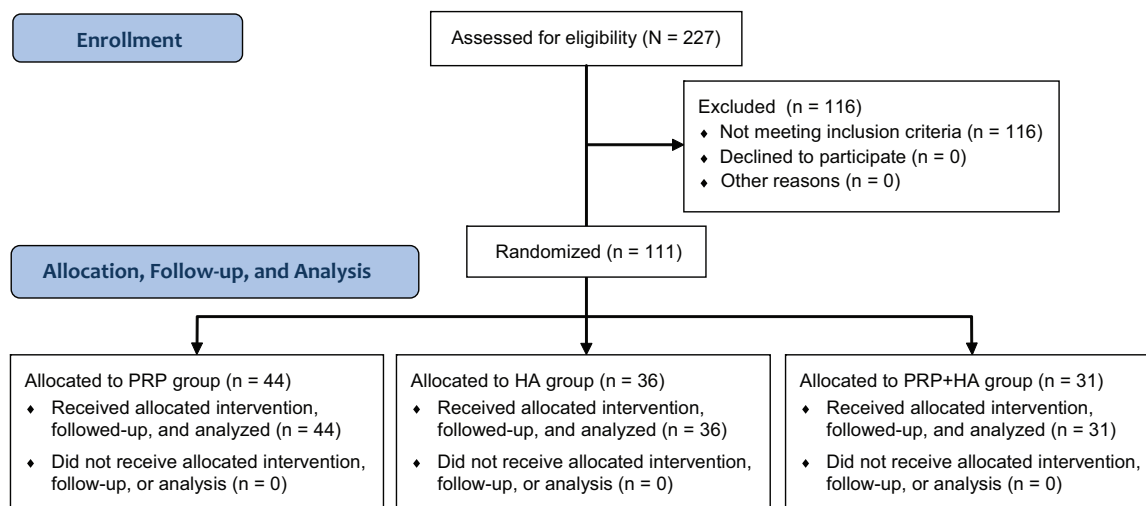


Figure 1. CONSORT (Consolidated Standards of Reporting Trials) flow diagram of the study. PRP, platelet-rich plasma.

viscoelasticity.^{6,24} The loss of normal characteristics of HA leads to the degradation of articular cartilage and the disruption of the mechanical homeostasis of the joint.¹⁸

Current nonoperative treatment strategies with both non-pharmacological and pharmacological therapies traditionally aim to reduce pain, stiffness, and physical disability³; intra-articular corticosteroid injections reduce pain and functional limitations,⁴ with a short-term benefit, but they are not able to change the natural history of the disease, and they can also have a negative effect on hip structures.⁸

The joints affected by OA have a lower than normal concentration of HA. Exogenous HA increases synovial fluid viscosity and enhances the shock absorption and lubricating capabilities of the synovial fluid. Moreover, it has been known to stimulate endogenous HA synthesis by synovial sites through CD44 receptor binding.²⁵ HA restores metabolic homeostasis, thereby reducing articular cartilage wear and pain.²⁷

One of the most interesting challenges of orthopaedics is finding innovative solutions to stimulating the repair of or replacing damaged cartilage.¹⁰ Many studies about tissue biology have shown the complex regulation of growth factors (GFs) for the normal tissue structure and reactions to tissue lesions.^{11,13}

Platelet-rich plasma (PRP) is a simple and low-cost option that provides a concentrate of natural, autologous blood GFs that can be used to enhance tissue regeneration.^{15,35} The influence of GFs on cartilage repair has been investigated and shown to promote cellular anabolism and tissue regeneration.^{17,19,29} PRP is currently hypothesized to largely control the activities of different cell types that target multiple biological processes, such as apoptosis, extracellular matrix synthesis, modulation of angiogenesis, and inflammation.¹⁹ In the literature, the best experience in intra-articular infiltrative therapy with PRP has been shown in the degenerative disease of the knee, with evidence of decreased pain and enhanced function in knee OA.^{15,20,29,31,34} To our knowledge, few studies have documented the role of PRP in the treatment of hip OA.^{4,5,32}

The first objective of this study was to evaluate the efficacy of intra-articular PRP injections in hip OA, comparing results with viscosupplementation with HA.^{12,14,16,21-23} The secondary objective was to evaluate the combined effect of metabolic stimulation on cartilage by autologous GFs and viscosupplementation induced by HA through the combined administration of PRP and HA. The last objective was to investigate the main GFs of PRP responsible for the clinical outcome.

METHODS

From April 2010 to December 2011, a total of 111 patients affected by hip OA were enrolled in a controlled randomized trial. The local ethics committee approved the study (authorization number 0020710), and all patients signed a detailed informed consent form. According to the American College of Rheumatology criteria, patients with a unilateral or bilateral degenerative disease with a history of chronic pain and functional impairment from at least 4 months were recruited.

The inclusion criteria were hip OA, Kellgren-Lawrence grades 1 to 4, always radiographically assessed by the same radiologist no more than 1 month before recruitment, and pain intensity at baseline of >20 on a 100-mm visual analog scale (VAS). The exclusion criteria were patients aged <18 or >65 years, protrusio acetabuli, concentric femoral head migration, extensive surgery of the reference joint (osteotomy around the hip, open or arthroscopic osteochondroplasty for femoroacetabular impingement), presence of an excessive deformity (acetabular or femoral head dysplasia, collapse deformity, and deformed femoral head sequelae of Perthes disease), and concomitant rheumatic diseases. Patients with systemic disorders such as diabetes, bleeding disorders, cardiovascular disease, infections, and immune system disorders were excluded from the protocol. Moreover, patients treated with antiplatelet agents or nonsteroidal anti-inflammatory drugs (NSAIDs)

TABLE 1
Number of Patients Enrolled in the Study
by Sex, Age, and Treatment Type^a

Age Group, y	Treatment Group, n			Total, n
	PRP (n = 44)	HA (n = 36)	PRP+HA (n = 31)	
Female				
<20	0	0	0	0
20-29	0	1	0	1
30-39	0	1	2	3
40-49	6	0	4	10
50-59	16	3	7	26
≥60	2	5	6	13
Total	24	10	19	53
Male				
<20	1	0	0	1
20-29	1	1	0	2
30-39	3	4	1	8
40-49	4	9	6	19
50-59	5	5	2	12
≥60	6	7	3	16
Total	20	26	12	58

^aHA, hyaluronic acid; PRP, platelet-rich plasma.

were asked, based on approval of their physician, to stop these therapies at least 3 days before the donation of blood necessary for the production of PRP. Concurrent medications, such as paracetamol or NSAIDs, were permitted but were discontinued

72 hours before clinical assessments. During the study, patients were also asked to suspend any drug treatments such as chondroprotective products.

Enrolled patients were randomly assigned at a 1:1:1 ratio to 1 of 3 groups through a computer-generated simple randomization system (Research Randomizer v 4.0³⁶): PRP, HA, and PRP+HA groups (Figure 1). The principal investigator (D.D.) secured the details of the series from all of the investigators; data collectors and outcome assessors (C.S., N.R., G.S., P.P.) were blinded to the type of treatment administered, whereas patients and health care providers, who received and provided the assigned treatments, respectively, were not blinded. At baseline, all patients underwent weightbearing anteroposterior radiography of the pelvis and were classified for the degree of OA according to the Kellgren-Lawrence grade. They were also clinically evaluated using the Harris Hip Score (HHS), Western Ontario and McMaster Universities Osteoarthritis Index (WOMAC), and VAS.

The patient sample size was calculated by using G*Power free software (Universities of Kiel, Düsseldorf, and Mannheim). The minimum sample size for each group of 30 patients was calculated by taking into account an effect size of VAS score at 12 months among groups of more than 0.35 for $P = .05$ and a power of at least 0.80.²⁶ Patient recruitment was stopped when the minimum number of patients was achieved in all groups; all patients recruited and allocated have been reported.

PRP Preparation

Patients of the PRP and PRP+HA groups underwent venous blood collection for the production of PRP. The limits of acceptable hemoglobin were defined at 11 mg/dL for both men and women, and the platelet count was also in excess of 150,000/mm³. The procedure for the production of the platelet gel consisted of the removal of 150 mL of peripheral blood for patients with a unilateral degenerative disease and 300 mL for those with a bilateral one through 2 centrifugations: the first to separate erythrocytes from platelets (1480 rpm for 6 minutes) and the second to concentrate them (3400 rpm for 15 minutes). The unit of PRP produced was then divided into 7 aliquots for patients with a bilateral disease and 4 aliquots for those with a unilateral disease, each consisting of 5 mL, and stored at -30°C. Randomly, PRP aliquots of at least 25% of patients (PRP group: n = 13; PRP+HA group: n = 8) were analyzed for the following proinflammatory and anti-inflammatory markers: interleukin-6 (IL-6), tumor necrosis factor- α (TNF α), interleukin-1 receptor antagonist (IL-1RA), interleukin-10 (IL-10), tissue inhibitor of metalloproteinases-1 (TIMP1), transforming growth factor- β 1 (TGF- β 1), and vascular endothelial growth factor (VEGF) using human enzyme-linked immunosorbent assay kits (Boster Immunoleader). Marker quantifications were obtained by an Imark microplate reader (Bio-Rad Laboratories). Before injections, the PRP units were thawed by putting them in a thermostat at 37°C for 30 minutes, and 1 mL of calcium chloride (10%) was added to activate the platelets.

Treatment Schedule

The treatment schedule was arbitrary based on the clinical literature on hip OA.²⁸ All patients received 3 consecutive intra-articular ultrasound-guided injections during outpatient surgery, 1 week apart, of 5 mL of autologous PRP (PRP group), 2 mL of HA (Hyalubrix 30 mg/2 mL; Fidia Farmaceutici SpA) (HA group), or 7 mL of PRP+HA (PRP:HA = 5:2 mL) (PRP+HA group).

The intra-articular injections were performed in sterile conditions; patients were placed in a supine position, and sterile draping was applied to the anterolateral region of the hip. A 2- to 5-MHz convex transducer sterile cover (Micromaxx Ultrasound System; SonoSite Inc) was positioned along the femoral neck axis. A 22-gauge spinal needle was inserted in the anterior capsular recess at the base of the femoral neck, moving it into caudocranial and lateromedial directions. Evacuation of the intra-articular fluid was performed at times, if needed. Finally, the patient was discharged with clear instructions to (1) restrict the use of the leg to normal daily activities for a few days, (2) avoid functional overloads, and (3) use the local application of ice as the only anti-inflammatory therapy.

Follow-up

Patients were evaluated at 2, 6, and 12 months after the last injection. Each time, a subjective assessment, the WOMAC and VAS, was performed, and a clinical

TABLE 2
Number of Hips Treated per Group According to Kellgren-Lawrence Grade and Sex,
and Percentage of Treated Hips per Total Number of Patients (n = 111)^a

Kellgren-Lawrence Grade	PRP Group			HA Group			PRP+HA Group			P Value ^b
	Female Hips, n	Male Hips, n	% of Patients	Female Hips, n	Male Hips, n	% of Patients	Female Hips, n	Male Hips, n	% of Patients	
1	9	5	13	3	7	9	4	4	7	.254
2	4	6	9	2	3	5	4	4	7	.899
3	5	5	9	4	8	11	10	4	13	.149
4	7	6	12	1	9	9	2	1	3	.057

^aHA, hyaluronic acid; PRP, platelet-rich plasma.

^bFisher exact test.

TABLE 3
Proinflammatory and Anti-inflammatory Markers Measured Randomly in the PRP and PRP+HA Groups^a

	PRP Group (n = 13)	PRP+HA Group (n = 8)	P Value ^b
IL-6, pg/mL	21 (0-63)	34 (0-130)	.408
TNF α , pg/mL	3 (0-7)	2 (0-7)	.204
IL-1RA, pg/mL	533 (106-1225)	500 (194-998)	.847
IL-10, pg/mL	1.4 (0.0-8.3)	1.0 (0.0-3.8)	.357
TIMP1, pg/mL	980 (607-1331)	1015 (158-1772)	.829
TGF- β 1, ng/mL	38 (15-88)	50 (17-98)	.258
VEGF, pg/mL	308 (63-572)	223 (107-366)	.170

^aData are reported as mean (range). HA, hyaluronic acid; IL-1RA, interleukin-1 receptor antagonist; IL-6, interleukin-6; IL-10, interleukin-10; PRP, platelet-rich plasma; TGF- β 1, transforming growth factor- β 1; TIMP1, tissue inhibitor of metalloproteinases-1; TNF α , tumor necrosis factor- α ; VEGF, vascular endothelial growth factor.

^bStudent *t* test.

evaluation was always carried out by the same orthopaedic surgeon by completing the HHS. At 12 months, a further radiological examination (pelvis and lateral hip affected) was performed. The primary outcome was an assessment of any change in pain intensity as measured by the VAS. Secondary outcomes were the HHS, WOMAC, measurements of the concentration of GFs in PRP, the proportion of responders (reduction in clinical scores of >30% from baseline to 12-month follow-up),³² and the correlation between the clinical outcomes and the PRP composition.

Statistical Analysis

Statistical analysis was performed using IBM SPSS Statistics 21 software. The data were expressed in terms of means with ranges or as boxplots. Differences in terms of age, sex, and OA grade were defined by the Fisher exact test. After having verified the normal distribution (Shapiro-Wilks test) and the homogeneity of variance (Levene test), the influence of treatments on HHS, WOMAC, and VAS scores at different follow-up times was investigated by a generalized linear model for repeated measures with treatment type and Kellgren-Lawrence grade as fixed effects and age and sex as covariates, followed by the Sidak multiple comparison test. The Student *t* test was used to compare the results of proinflammatory and anti-inflammatory markers between the PRP and PRP+HA groups. Finally, correlations between the

results of proinflammatory and anti-inflammatory markers and HHS, WOMAC, and VAS scores at different follow-up times were evaluated, controlling for the effects of treatment type and Kellgren-Lawrence grade. In the same way, correlations between proinflammatory and anti-inflammatory markers of variations of HHS, WOMAC, and VAS scores from baseline to 12 months (expressed as geometric means) were also investigated.

RESULTS

Tables 1 and 2 report the demographic data of enrolled patients: 44 patients were assigned to PRP treatment, 31 patients to PRP+HA treatment, and 36 patients to HA treatment. There were no withdrawals, losses at follow-ups, or crossovers. The same number of group-assigned patients received the intended treatment and was analyzed for outcomes according to the intention-to-treat analysis. The 3 groups were homogeneous for age ($P = .176$) and Kellgren-Lawrence grade ($P = .417$) but not for sex, showing significant differences among groups, with a prevalence of male patients ($P = .012$). No complications related to the infiltrations were observed during treatment and the follow-up period, apart from a transient pain reaction observed in the PRP+HA group in 13 patients, which spontaneously resolved within the treatment period. The results of proinflammatory and anti-inflammatory markers measured in

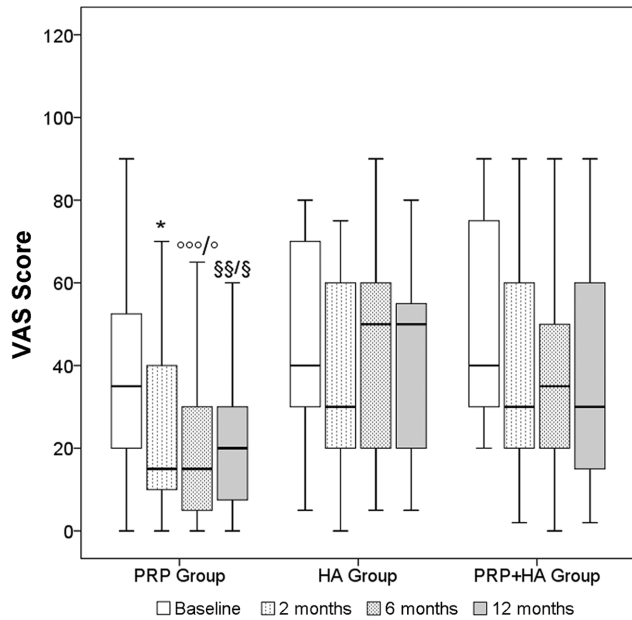


Figure 2. Visual analog scale (VAS; 0-100 points) scores for each type of treatment during follow-up. The horizontal black line represents the median, the box limit represents quartiles, and error bars represent 95% CIs. Sidak test: *PRP vs HA ($P = .026$) and PRP vs PRP+HA ($P = .010$) at 2 months; °°°PRP vs HA at 6 months ($P < .0005$); °PRP vs PRP+HA at 6 months ($P = .007$); §§PRP vs HA at 12 months ($P = .002$); §PRP vs PRP+HA at 12 months ($P = .017$). HA, hyaluronic acid; PRP, platelet-rich plasma.

PRP of both the PRP group and PRP+HA group did not show significant differences (Table 3).

The multivariate generalized linear model repeated-measures analysis showed the same significant improvement in VAS, HHS, and WOMAC scores during time (Wilks λ : .768 [VAS], $P < .0005$; .754 [HHS], $P < .0005$; .754 [WOMAC], $P < .0005$), with significant interactions for VAS ($F = 6.104$; $P = .003$) and WOMAC ($F = 6.477$; $P = .002$) scores with treatment type (Figures 2-4). At the 2-month follow-up, the PRP group showed higher values in terms of the WOMAC score (mean, 73; 95% CI, 68-78) and lower values in terms of the VAS score (mean, 23; 95% CI, 16-29) compared with the HA (mean WOMAC: 59 [95% CI, 53-6], $P = .009$; mean VAS: 38 [95% CI, 30-46], $P = .026$) and PRP+HA (mean WOMAC: 59 [95% CI, 52-64], $P = .002$; mean VAS: 35 [95% CI, 26-45], $P = .010$) groups. At the 6-month follow-up, the trend was similar, showing again that the PRP group had higher values in terms of the WOMAC score (mean, 72; 95% CI, 67-76) and lower values in terms of the VAS score (mean, 21; 95% CI, 15-28) compared with the HA (mean WOMAC: 59 [95% CI, 54-65], $P = .009$; mean VAS: 44 [95% CI, 36-52], $P < .0005$) and PRP+HA (mean WOMAC: 59 [95% CI, 54-66], $P = .005$; mean VAS: 35 [95% CI, 26-45], $P = .007$) groups (Figures 2 and 4). Finally, the comparative analysis at the 12-month follow-up showed the loss of statistical significance in terms of the WOMAC score among groups, maintaining

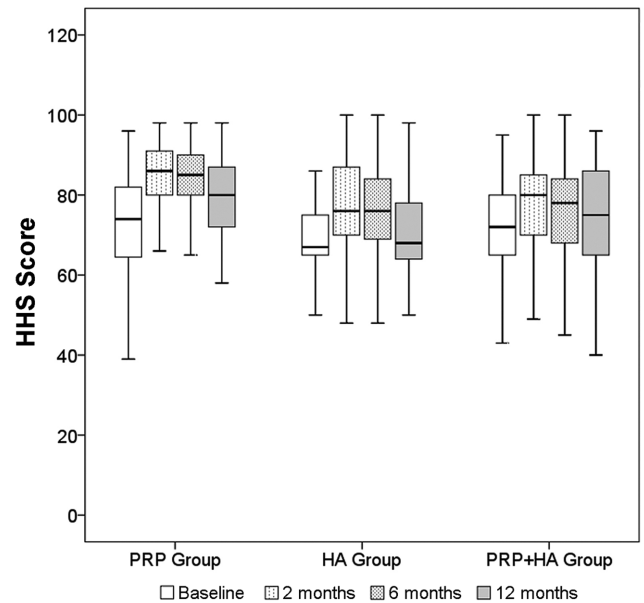


Figure 3. Harris Hip Score (HHS; 0-100 points) results for each type of treatment during follow-up. The horizontal black line represents the median, the box limit represents quartiles, and error bars represent 95% CIs. Sidak test: nonsignificant. HA, hyaluronic acid; PRP, platelet-rich plasma.

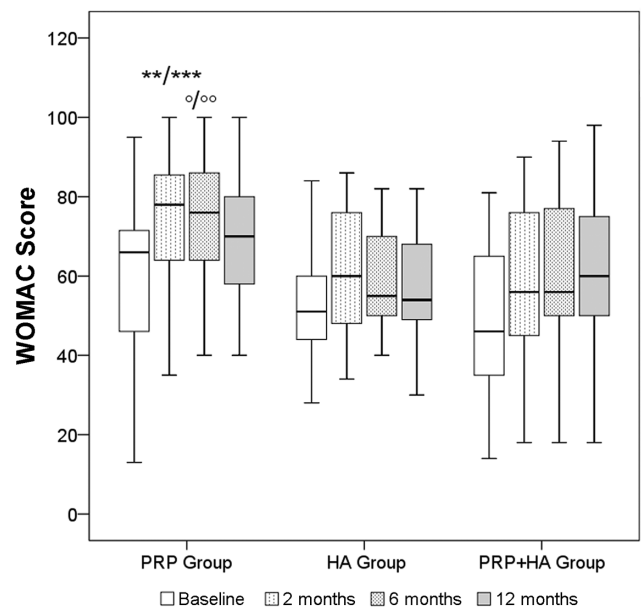


Figure 4. Western Ontario and McMaster Universities Osteoarthritis Index (WOMAC; 0-100 points) scores for each type of treatment during follow-up. The horizontal black line represents the median, the box limit represents quartiles, and error bars represent 95% CIs. Sidak test: *PRP vs HA ($P = .009$) at 2 months; **PRP vs PRP+HA at 2 months ($P = .002$); °PRP vs HA at 6 months ($P = .009$); °°PRP vs PRP+HA at 6 months ($P = .005$). HA, hyaluronic acid; PRP, platelet-rich plasma.

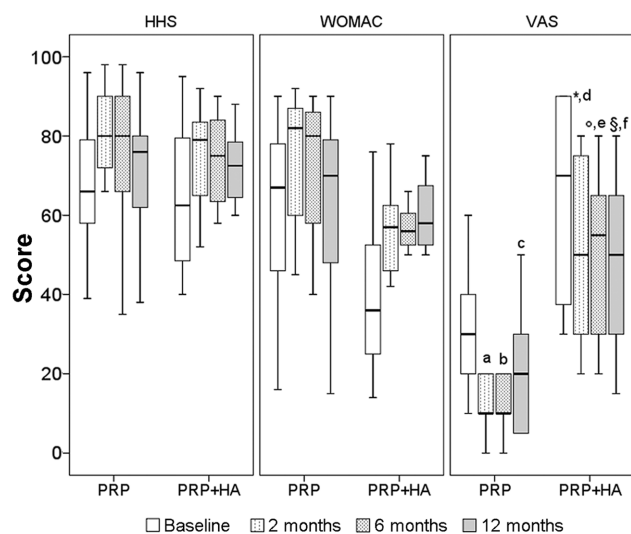


Figure 5. Harris Hip Score (HHS), Western Ontario and McMaster Universities Osteoarthritis Index (WOMAC), and visual analog scale (VAS) results for patients in the PRP and PRP+HA groups, whose PRP aliquots were analyzed for proinflammatory and anti-inflammatory markers. The horizontal black line represents the median, the box limit represents quartiles, and error bars represent 95% CIs. Sidak test: PRP vs PRP+HA *at 2 months ($P = .020$), °at 6 months ($P = .007$), §at 12 months ($P = .037$); PRP at °2 months vs baseline ($P = .003$), °6 months vs baseline ($P < .0005$), °12 months vs baseline ($P = .007$); PRP+HA at °2 months vs baseline ($P = .021$), °6 months vs baseline ($P = .002$); §12 months vs baseline ($P = .002$). HA, hyaluronic acid; PRP, platelet-rich plasma.

a meaningful trend only for the VAS score: PRP (mean, 24; 95% CI, 17-30) versus HA (mean, 42; 95% CI, 34-50; $P = .002$) and PRP+HA (mean, 38; 95% CI, 28-47; $P = .017$).

There were positive responders at 12 months after treatment: 10 of 47 hips (21.2%), 6 of 37 hips (16.2%), and 13 of 33 hips (39.4%) for the PRP, HA, and PRP+HA groups, respectively, as assessed by the WOMAC, with a significant difference among groups ($P = .040$). No significant differences were found among groups for positive responders at 12 months after treatment assessed by the VAS and HHS.

The HHS, WOMAC, and VAS results of patients whose PRP aliquots were analyzed for proinflammatory and anti-inflammatory markers are reported in Figure 5 (PRP group: $n = 13$; PRP+HA group: $n = 8$). The multivariate generalized linear model repeated-measures analysis showed a significant improvement in VAS scores during time for the PRP and PRP+HA groups (Figure 5) and significant differences at each follow-up time between the PRP+HA and PRP groups (2 months: mean difference, 28.9 [$P = .020$]; 6 months: mean difference, 29.6 [$P = .007$]; 12 months: mean difference, 23.9 [$P = .037$]). No significant improvements for HHS and WOMAC scores were observed within these selected patients. Finally, a significant correlation between the anti-inflammatory IL-10 marker and variations of the VAS score during time was found ($r = 0.392$; $P = .040$), considering also

the effects of treatment type and Kellgren-Lawrence grade (partial correlation $r = 0.505$; $P = .014$).

DISCUSSION

The aim of this study was to evaluate the efficacy of intra-articular PRP injections in hip OA, comparing results with viscosupplementation with HA. The current trial data showed that, as for the duration of the benefits obtained, the improvement in clinically relevant scores was stable within 6 months in all groups. At the latest follow-up at 12 months postoperatively, almost all of the patients showed a decrease in clinical outcomes, with the least reduction in the PRP group. The efficacy of intra-articular PRP injections in hip OA compared with HA or PRP+HA was observed from baseline to the 6-month follow-up by a significant improvement in WOMAC and VAS scores but not in HHS values. From 6 months to 12 months, a decrease in WOMAC and VAS scores was demonstrated, even though the VAS scores achieved with the PRP group were significantly better than those with HA or PRP+HA. The percentage of positive responders confirmed the positive role of PRP in reducing the painful component more effectively than that of HA separately or in combination with HA. The intra-articular treatments showed no relevant side effects; the higher pain reaction observed in the PRP+HA group was probably caused by a dilution in the amount of PRP GFs or by excessive capsular distension-by-volume effect, even though 9 mL is considered the upper limit value for intra-articular injections in the hip.³⁷

Intra-articular injections in OA have 2 major objectives: to relieve pain and to reduce functional disability. Extensive data in the literature indicate that the intra-articular administration of HA is capable of restoring the viscoelastic properties of the synovial fluid in the knee joint, with relief of pain and improvement of joint mobility.^{30,31} Previous reports documented results of PRP in the treatment of degenerative knee lesions,^{10,11,33} with encouraging improvement in the clinical scores adopted. Filardo et al¹⁰ reported that clinical improvement in intra-articular therapy with PRP is time dependent, with an average duration of 9 months, and that better and longer lasting results were achieved in younger patients with lower levels of joint degeneration. In 2012, by comparing PRP to HA, they did not demonstrate improved results in patients treated for knee OA but indicated that there was a trend toward better results with PRP at 6 and 12 months of follow-up.¹¹ However, Spaková et al³³ observed a statistically significant improvement in the clinical score at 3 and 6 months of follow-up in the PRP group compared with HA.

Few reports have investigated the efficacy of PRP injections for the treatment of hip OA.^{4,5,32} Sánchez et al³² reported on a preliminary noncontrolled prospective study, demonstrating encouraging results of PRP in patients affected by hip OA and suggesting a randomized clinical study to support the safety and efficacy of the treatment. Battaglia et al^{4,5} stated that intra-articular injections of PRP are efficacious in terms of functional improvement and pain reduction but are not superior to HA in patients

with symptomatic hip OA at 12-month follow-up. In the literature, no randomized clinical trial investigated results at 1-year follow-up in patients suffering from symptomatic hip OA after intra-articular injections with autologous PRP, HA, or both. Moreover, there is a lack of knowledge on the mechanism by which PRP exerts its role. Current research is investigating new methods for stimulating the repair of damaged cartilage by intra-articular injections: PRP exerts multiple biological actions, including modulatory effects on inflammation and angiogenesis, which may translate clinically to pain relief.^{11,13} In addition, the molecular complexity of PRP is crucial, suggesting that it can interfere with chondrocyte apoptosis and mediate other cellular mechanisms, such as cell migration, proliferation, or anabolic actions of chondrocytes.³²

Another aim of the study was to investigate the main GFs of PRP responsible for the clinical outcome. The current data demonstrated that there were significant correlations between IL-10 and variations of the VAS score. These effects were not because of preexisting differences in the concentrations of such factors, as evidenced in the contents of GF found at baseline. IL-10 is a pleiotropic cytokine with anti-inflammatory and chondroprotective functions: it suppresses the release of inflammatory mediators by macrophages such as TNF α , IL-6, and IL-1 β ; blocks the inflammatory pathway by neutralizing nuclear factor- κ B activity; and prevents chondrocyte apoptosis.⁷ On this basis, the present study found correlations among IL-10 and pain and quality of life, suggesting that PRP infiltrations in hips affected by OA could exert beneficial effects through an increase of IL-10. The discrepancies found in patients' responses in other studies can be related to different PRP formulations because almost all clinical studies did not investigate the contents of GFs.^{4,5,32} Until now, to our knowledge, there have been no clinical trials investigating the amount and roles of GFs contained in PRP in directing the clinical outcomes of patients affected by hip OA.

The major limitations of the current study were the lack of blinding of patients and treating physicians that would avoid performance bias and not having performed proinflammatory and anti-inflammatory marker analyses and the relative correlation with the clinical outcomes in all patients. However, this study provided insight into the therapeutic potential and limitations of PRP injections or PRP+HA for hip OA as well as some correlation between tested PRP markers and clinical results. Another limitation was the absence of a gold standard or true control group such as a sham treatment with saline. Even though saline injections would have afforded the greatest value in design, the best active and clinically accepted treatment, as HA injections, was preferred in consideration that injections in the hip are a nonoperative but invasive procedure (more so than in the knee). Strengths of the study were the clinical relevance and the minimization of assignment and assessment bias through randomization and blinding of data outcome assessors and collectors, respectively. Another strength resided in the great clinical applicability of this study because of the choice of a heterogeneous cohort of study participants with a wide range of OA stages at a tertiary health care center.

In conclusion, the current results indicated that intra-articular PRP injections offer a significant clinical improvement in hip OA, better than HA alone or combined with HA. In the hip, the treatment has the potential to reduce pain and improve function and quality of life. Moreover, a significant "moderate" correlation was found between the content of IL-10 in PRP and the reduction of pain, although in a limited number of patients. Further research, such as meta-analyses and double-blinded trials with more patients and with a placebo group, is needed to better elucidate the safety and efficacy of autologous platelet derivatives for the treatment of hip OA.

ACKNOWLEDGMENT

The authors thank Dr Annarita Cenacchi of Immunohematology and Transfusion Medicine of the Rizzoli Orthopedic Institute for platelet-rich plasma preparation and Dr Claudia Balugani for her kind assistance in English correction.

REFERENCES

1. Abate M, Pelotti P, De Amicis D, Di Iorio A, Galletti S, Salini V. Viscosupplementation with hyaluronic acid in hip osteoarthritis. *Upsal J Med Sci.* 2008;113:261-277.
2. Anitua E, Sánchez M, Nurden AT, Nurden P, Orive G, Andia I. New insights into and novel applications for platelet-rich fibrin therapies. *Trends Biotechnol.* 2006;24:227-234.
3. Anitua E, Sánchez M, Nurden AT, et al. Platelet-released growth factors enhance the secretion of hyaluronic acid and induce hepatocyte growth factor production by synovial fibroblasts from arthritic patients. *Rheumatology.* 2007;46:1769-1772.
4. Battaglia M, Guaraldi F, Vannini F, et al. Platelet-rich plasma (PRP) intra-articular ultrasound-guided injections as a possible treatment for hip osteoarthritis: a pilot study. *Clin Exp Rheumatol.* 2011;29:754.
5. Battaglia M, Guaraldi F, Vannini F, et al. Efficacy of ultrasound-guided intra-articular injections of platelet-rich plasma versus hyaluronic acid for hip osteoarthritis. *Orthopedics.* 2013;36:e1501-e1508.
6. Chen YQ, Chou PL, Cheng CY, et al. Microrheology of human synovial fluid of arthritis patients studied by diffusing wave spectroscopy. *J Biophotonics.* 2012;5:777-784.
7. Civinini R, Nistri L, Martini C, Redl B, Ristori G, Innocenti M. Growth factors in the treatment of early osteoarthritis. *Clin Cases Miner Bone Metab.* 2013;10:26-29.
8. Cole BJ, Seroyer ST, Filardo G, Bajaj S, Fortier LA. Platelet-rich plasma: where are we now and where are we going? *Sports Health.* 2010;2:203-210.
9. Dawson J, Linsell L, Zondervan K, et al. Epidemiology of hip and knee pain and its impact on overall health status in older adults. *Rheumatology.* 2004;43:497-504.
10. Filardo G, Kon E, Buda R, et al. Platelet-rich plasma intra-articular knee injections for the treatment of degenerative cartilage lesions and osteoarthritis. *Knee Surg Sports Traumatol Arthrosc.* 2011;19:528-535.
11. Filardo G, Kon E, Di Martino A, et al. Platelet-rich plasma vs hyaluronic acid to treat knee degenerative pathology: study design and preliminary results of a randomized controlled trial. *BMC Musculoskelet Disord.* 2012;13:229.
12. Foti C, Cisari C, Carda S, et al. A prospective observational study of the clinical efficacy and safety of intra-articular sodium hyaluronate in synovial joints with osteoarthritis. *Eur J Phys Rehabil Med.* 2011;47:407-415.
13. Frisbie DD, Kawcak CE, Werpy NM, Park RD, McIlwraith CW. Clinical, biochemical, and histologic effects of intraarticular administration of autologous conditioned serum in horses with experimentally induced osteoarthritis. *Am J Vet Res.* 2007;68:290-296.

14. Giarratana LS, Marelli BM, Crapanzano C, et al. A randomized double-blind clinical trial on the treatment of knee osteoarthritis: the efficacy of polynucleotides compared to standard hyaluronan viscosupplementation. *Knee*. 2014;21:661-668.
15. Gobbi A, Bathan L. Biological approaches for cartilage repair. *J Knee Surg*. 2009;22:36-44.
16. Guidolin D, Franceschi F. Viscosupplementation with high molecular weight native hyaluronan: focus on a 1500-2000 KDa fraction (Hyalubrix®). *Eur Rev Med Pharmacol Sci*. 2014;18:3326-3338.
17. Hickey DG, Frenkel SR, Di Cesare PE. Clinical applications of growth factors for articular cartilage repair. *Am J Orthop*. 2003;32:70-76.
18. Hunter DJ. Viscosupplementation for osteoarthritis of the knee. *N Engl J Med*. 2015;372(11):1040-1047.
19. Juhakoski R, Heliövaara M, Impivaara O, et al. Risk factors for the development of hip osteoarthritis: a population based prospective study. *Rheumatology*. 2009;48:83-87.
20. Kon E, Buda R, Filardo G, et al. Platelet-rich plasma: intra-articular knee injections produced favorable results on degenerative cartilage lesions. *Knee Surg Sports Traumatol Arthrosc*. 2010;18:472-479.
21. McAlindon TE, Bannuru RR, Sullivan MC, et al. OARSI guidelines for the non-surgical management of knee osteoarthritis. *Osteoarthritis Cartilage*. 2014;22:363-388.
22. Migliore A, Bella A, Bisignani M, et al. Total hip replacement rate in a cohort of patients affected by symptomatic hip osteoarthritis following intra-articular sodium hyaluronate (MW 1,500-2,000 kDa) ORTOBRIX study. *Clin Rheumatol*. 2012;31:1187-1196.
23. Migliore A, Massafra U, Bizzi E, et al. Comparative, double-blind, controlled study of intra-articular hyaluronic acid (Hyalubrix) injections versus local anesthetic in osteoarthritis of the hip. *Arthritis Res Ther*. 2009;11:R183.
24. Milas M, Rinaudo M, Roure I, Al-Assaf S, Phillips GO, Williams PA. Comparative rheological behavior of hyaluronan from bacterial and animal sources with cross-linked hyaluronan (hylan) in aqueous solution. *Biopolymers*. 2001;59:191-204.
25. Moreland LW. Intra-articular hyaluronan (hyaluronic acid) and hylans for the treatment of osteoarthritis: mechanisms of action. *Arthritis Res Ther*. 2003;5:54-67.
26. Qvistgaard E, Christensen R, Torp-Pedersen S, Bliddal H. Intra-articular treatment of hip osteoarthritis: a randomized trial of hyaluronic acid, corticosteroid, and isotonic saline. *Osteoarthritis Cartilage*. 2006;14:163-170.
27. Reid MC. Viscosupplementation for osteoarthritis: a primer for primary care physicians. *Adv Ther*. 2013;30:967-986.
28. Richette P, Ravaud P, Conrozier T, et al. Effect of hyaluronic acid in symptomatic hip OA: a multicenter randomized, placebo controlled trial. *Arthritis Rheum*. 2009;60:824-830.
29. Rodriguez-Merchan EC. Intraarticular injections of platelet-rich plasma (PRP) in the management of knee osteoarthritis. *Arch Bone J Surg*. 2013;1:5-8.
30. Sampson S, Reed M, Silvers H, Meng M, Mandelbaum B. Injections of platelet-rich plasma in patients with primary and secondary knee osteoarthritis. *Am J Phys Rehabil*. 2010;89:961-969.
31. Sánchez M, Anita E, Azofra J, Aguirre JJ, Andia I. Intra-articular injection of an autologous preparation rich in growth factor for the treatment of knee OA: a retrospective cohort study. *Clin Exp Rheumatol*. 2008;26:910-913.
32. Sánchez M, Guadilla J, Fiz N, Andia I. Ultrasound-guided platelet-rich plasma injections for the treatment of osteoarthritis of the hip. *Rheumatology*. 2012;51:144-150.
33. Spaková T, Rosocha J, Lacko M, Harvanová D, Gharaibeh A. Treatment of knee joint osteoarthritis with autologous platelet-rich plasma in comparison with hyaluronic acid. *Am J Phys Med Rehabil*. 2012;91:411-417.
34. Tietze DC, Geissler K, Borchers J. The effects of platelet-rich plasma in the treatment of large-joint osteoarthritis: a systematic review. *Phys Sportsmed*. 2014;42:27-37.
35. Tschon M, Fini M, Giardino R, et al. Lights and shadows concerning platelet products for musculoskeletal regeneration. *Front Biosci (Elite Ed)*. 2011;3:96-107.
36. Urbaniak GC, Plous S. Research Randomizer (Version 4.0) 2013 [computer software]. Available at: <http://www.randomizer.org/>. Accessed June 22, 2013.
37. Young R, Harding J, Kingsly A, Bradley M. Therapeutic hip injections: is the injection volume important? *Clin Radiol*. 2012;67:55-60.

For reprints and permission queries, please visit SAGE's Web site at <http://www.sagepub.com/journalsPermissions.nav>.